

Pattern of Neonatal Intestinal Obstruction in a Tertiary Care Hospital and its Management: A Prospective Study

LAXMIKANTA MOHAPATRA, PRASANTA KUMAR TRIPATHY, PRADEEP KUMAR JENA, HIRANYA KISHOR MOHANTY

ABSTRACT

Introduction: Intestinal obstructions are the most common conditions in neonates, requiring emergency surgical intervention. The management and outcome are challenging particularly in a developing country.

Aim: To find the pattern of neonatal intestinal obstruction, the management approach and outcome in a paediatric surgery centre in Eastern India.

Materials and Methods: This prospective cohort study was conducted in Department of Paediatric Surgery of SVP Postgraduate Institute of Paediatric, SCB Medical College, Cuttack, Odisha, India. It was conducted over a period of two years from October 2016 to September 2018. Patients with oesophageal atresia and anorectal malformation were excluded from the study.

Results: Out of 126 newborns included in the study, intestinal atresia (56 cases) was the leading cause of obstruction and was found most commonly at the level of jejunum. A case of pyloric atresia associated with epidermolysis bullosa, a case of apple-peel type of intestinal atresia associated with jejunal

duplication cyst and a case of colonic atresia associated with anorectal malformation were rare findings detected in the study. Hirschsprung's disease was the second most common pathology, found in 42 cases. Laparotomy, levelling biopsy and colostomy was done in all cases of Hirschsprung's disease. Malrotation (14 cases) and Meconium ileus (12 cases) were also important causes of neonatal intestinal obstruction. Fourteen cases (11.1%) died during hospitalisation and septicaemia was the common cause of morbidity and mortality.

Conclusion: Intestinal atresias are the most common cause of neonatal intestinal obstruction in our study (44% cases) followed by Hirschsprung's disease (33% cases). Male newborns were more commonly affected and majority of neonates presented during first week of life. Post-operative septicaemia, pneumonia and wound infection should be adequately managed. Early recognition of the problem and referral from peripheral hospitals in recent years were important for improved survival (89%) in the present study. Urgent resuscitation, diagnosis, surgical intervention and utmost utilization of available neonatal supporting system are the key factors.

Keywords: Hirschsprung's disease, Intestinal atresia, Malrotation, Meconium ileus

INTRODUCTION

One of the most common surgical emergencies encountered in neonatal age group is mechanical intestinal obstruction [1]. The incidence of neonatal intestinal obstruction is reported as 1 in 1500 live births [2]. The management and outcome are challenging especially in a developing country. Abdominal distension, bilious vomiting, non-passage or delayed passage of meconium and visible bowel loops are the usual presenting feature. However, the leading cause of intestinal obstruction varies in different regions of world [3]. Intestinal atresia, meconium ileus, malrotation and Hirschsprung's disease are the causes of obstruction in newborn period [4].

In comparison to developed western countries, the mortality rate in developing countries like India is higher due to low birth

weight, late transport from periphery to specialty hospital and inadequate infrastructure/ intensive care units [5]. Prematurity and associated congenital anomalies are added risk factors.

The pattern of neonatal obstruction, the management approach and outcome varies in different regions of India. Evaluation of the scenario in present region will help in improving the treatment and outcome in such emergency conditions. Thus, the present study aimed to find the pattern of intestinal obstruction in newborns, the management approach and outcome in our surgical set-up.

MATERIALS AND METHODS

This prospective cohort study was conducted in the Department of Pediatric surgery, SVP Postgraduate Institute of Pediatrics,

SCB Medical College, Cuttack, Odisha, India over a period of two years from October 2016 to September 2018. A convenient sampling method was used where all cases admitted to the department were recruited as per inclusion criteria. Parental consents were taken as per proforma.

Neonates (1-28 days of age), operated for intestinal obstruction were included in the study. Patients with oesophageal atresia, congenital hypertrophic pyloric stenosis and anorectal malformations were excluded from the study. Patients admitted, but not operated due to severe sepsis, very low birth weight and parental unwillingness were also excluded from the study.

All the patients were admitted on emergency basis in warmer beds. They received immediate resuscitation with nasogastric drainage, intravenous fluids and broad-spectrum antibiotics. Plain radiograph of abdomen in erect posture, haemogram and serum electrolytes were done in all cases. Ultrasonography of abdomen and contrast studies were done in selected cases. Correction of dehydration and electrolyte imbalance was given utmost importance. Laparotomy was done under general anaesthesia in all but, the surgical procedure varied according to the pathology. The excised specimens and biopsy materials were sent for histopathological study. Blood transfusion was given whenever required intraoperatively or afterwards. Post-operative cares continued and the sick patients were shifted to intensive care unit. Patients were discharged only after adequate oral feeds. They were advised to attend OPD with histopathology report and followed for six months. The outcome was recorded in terms of survival, complications and duration of hospitalisation.

STATISTICAL ANALYSIS

Statistical analysis was presented as percentage, chi-square test was used for comparisons of outcomes in different causes of intestinal obstruction. p-value <0.05 was taken to be significant.

RESULTS

A total of 428 newborn surgeries were performed during the two-year period, out of which 126 cases (29.44%) were having intestinal obstruction. The age range was 1-28 days and the mean age of presentation was 5.9 days. Seventy-six patients (60.3%) presented before one week of age and 50 patients (39.7%) presented after one week of age. The gestational age of these newborns varied between 32 weeks to 42 weeks. There were 83 male neonates (65.9%) and 43 female neonates (34.1%) with a resultant male to female ratio of 1.9:1. At presentation the weight was between 1.3 kg to 3.9 kg (mean=2.3 kg) and 21 cases were below 2 kg.

Abdominal distension (79.4%), bilious vomiting (73%), non-passage of meconium (47.6%) and visible bowel loops (35.7%) were the complaints during admission [Table/Fig-1].

Symptomatology	No. of cases	Frequency (%)
Abdominal distension	100	79.4
Bilious vomiting	92	73
Nonpassage of meconium	60	47.6
Visible bowel loops	45	35.7

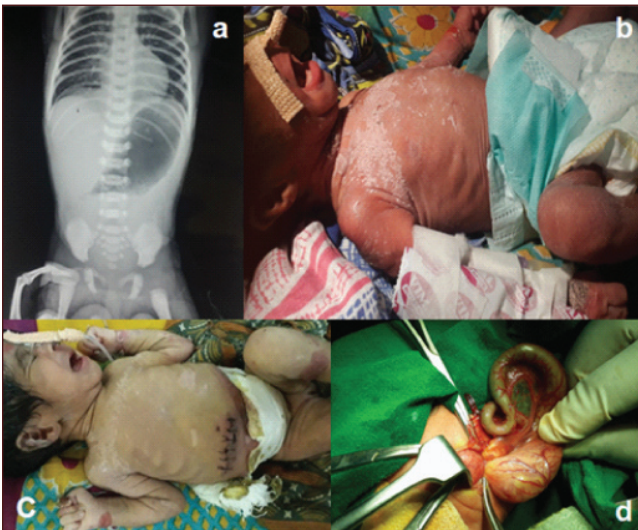[Table/Fig-1]: Mode of clinical presentation and frequency in neonatal intestinal obstruction (n=126).

Intestinal atresia was the most common cause of obstruction, found in 56 cases. Atresia was at the level of pylorus in one case, duodenum in 17 cases, jejunum-ileum in 36 cases and colon in 2 cases [Table/Fig-2]. One pyloric atresia patient had epidermolysis bullosa as an associated finding [Table/Fig-3]. Down syndrome was associated in four cases of duodenal atresia. Type I (mucosal web) duodenal atresia was found in 11 cases; excision of duodenal web and transverse duodenoplasty was done in these cases. Type III anomaly (atresia with a gap between two blind ending duodenal segments) was found in six cases and diamond shaped duodeno-duodenostomy was performed. Jejunum-ileal atresias were found in 36 cases. Laparotomy was done by right supraumbilical transverse incision in these cases and extended to left side when required. Resection of proximal dilated intestine and end-to-oblique anastomosis between two atretic segments were the most common surgical procedure. Apple-peel type of jejunum-ileal atresia was found in two neonates. Both the newborns were of low birth weight and one of these cases had an associated jejunal duplication cyst. Colonic atresia was detected in two patients, out of which one had anorectal malformation as an association. Laparotomy and end-to-back colo-colic anastomosis was done in both these cases with addition of colostomy proximal to anastomosis in one case.

Causes	No. of Cases	Incidence
Pyloric atresia	1	0.8 %
Duodenal atresia	17	13.5 %
Jejunum-ileal atresia	36	28.6%
Malrotation	14	11.1%
Meconium ileus	12	9.5%
Necrotizing enterocolitis	2	1.6%
Colonic atresia	2	1.6%
Hirschsprung's disease	42	33.3%

[Table/Fig-2]: Pattern of neonatal intestinal obstruction and incidence.

Hirschsprung's disease was suspected in 42 cases preoperatively. During laparotomy multiple levelling biopsy and colostomy was done in these cases [Table/Fig-4]. The first seromuscular biopsy was taken at the peritoneal reflection, the second one usually 10-15 cm proximal to peritoneal reflection and the third one at the colostomy site. Classical recto-sigmoid Hirschsprung's disease was the laparotomy picture in 36 cases

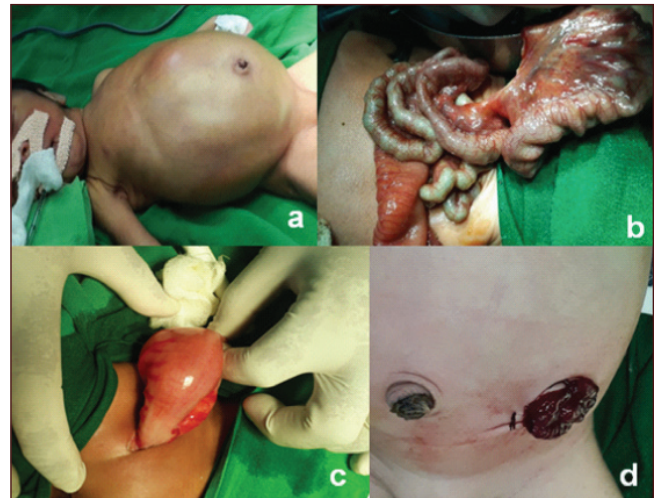


[Table/Fig-3]: Intestinal atresia: (a) Plain radiograph showing single gas shadow suggestive of pyloric atresia; (b) Associated with epidermolysis bullosa; (c) Postoperative picture of pyloric atresia; (d) Intraoperative photograph of Type I colonic atresia.

Etiology	Procedure	No. of cases
Hirschsprung's disease	Laparotomy, levelling biopsy and colostomy	42
Duodenal Atresia Type I	Excision of duodenal web and duodenoplasty	11
Duodenal Atresia Type III	Duodeno-duodenostomy	6
Jejuno-ileal Atresia (n=36) and NEC (n=2)	Resection and anastomosis of small intestine	38
Colonic Atresia	Colo-colic anastomosis	2
Malrotation	Ladd's procedure	16
Meconium ileus	Laparotomy and decompression	8
Meconium ileus	Decompression and cutaneous stoma	4
Colonic Atresia	Sigmoid colostomy for associated ARM	1
Jejunal Atresia	Excision of associated jejunal duplication cyst	1

[Table/Fig-4]: Showing different surgical procedures performed.

and the present authors performed sigmoid loop colostomy in these cases [Table/Fig-5]. Transverse loop colostomy was performed in six cases as the transition zone was proximal to sigmoid colon. Out of 12 cases of meconium ileus, eight cases were managed with enterotomy, decompression and closure of enterotomy. A cutaneous stoma was created after enterotomy in four cases; Mikulicz procedure in two cases, Bishop-Koop in one case and Santulli procedure in one case. Malrotation was found in 14 cases and Ladd's procedure was performed



[Table/Fig-5]: Neonatal intestinal obstruction: (a) Newborn with abdominal distension and visible bowel loops; (b) Intraoperative photograph showing meconium ileus; (c) Intraoperative picture in Hirschsprung's disease; proximal dilated sigmoid colon, a transition zone followed by distal narrowing; (d) Sigmoid colostomy done after levelling biopsy.

in these neonates. Two cases of necrotizing enterocolitis with bowel gangrene and perforation were operated during the above period. Laparotomy, excision of gangrenous segment bearing perforation, peritoneal lavage and end to end anastomosis was done in both the cases. Associated anomalies were detected in 11 cases (9%), out of which Down's syndrome was most common in six cases followed by malrotation in two cases. Anorectal malformation, epidermolysis bullosa and jejunal duplication cyst were also found as isolated associations.

A total number of 26 cases were transferred to Intensive care unit postoperatively and 18 of these newborns were supported by mechanical ventilator. Septicaemia (11.1%) was the most common and fatal complication encountered during hospitalisation followed by wound infection (9.5%), pneumonia (7.1%) and anastomotic leak (2.4%). Fourteen cases expired during hospitalisation due to septicaemia and pneumonia. Rest 112 cases were discharged and advised to attend OPD for follow-up at two weeks, later followed every month for six months. The average duration of hospitalisation was 8.5 days. The outcome of the study in different groups of intestinal obstruction was described and analyzed statistically [Table/Fig-6].

DISCUSSION

Neonatal intestinal obstructions are most common surgical emergencies in newborns [1,6]. In the present study, neonatal intestinal obstruction accounted for 29.4% of operations in newborn period. Atresia can occur at any part of gastrointestinal tract from oesophagus to rectum. The clinical presentation and operative management of oesophageal atresia are different from intestinal atresia. Anorectal Malformations (ARM) are traditionally categorised under a separate classification system

Disease pattern	No. of cases	Complications	p-value	Mortality	p-value
Intestinal Atresia	56	19	0.84	7	0.78
Hirschsprung's disease	42	10	0.43	2	0.22
Malrotation	14	3	0.49	2	0.72
Meconium Ileus	12	4	0.81	2	0.56
NEC	2	2	0.26	1	0.08
Total	126	38		14	

[Table/Fig-6]: Outcome in neonatal intestinal obstruction in terms of morbidity and mortality.

along with rectal atresia. So, the present authors have excluded esophageal atresia and ARM cases in the study. Male neonates with intestinal atresia were more common than females with a M:F ratio of 1.9:1. This male predominance (M:F=1.8:1) was also noted in similar published series [7,8].

Intestinal atresia was the most common cause of neonatal intestinal obstruction in the series (44% cases) followed by Hirschsprung's disease. Similar findings were reported by Pathak M et al., and Verma A et al., [8,9]. However, the studies conducted by Saha AK et al., from Bangladesh and Ameh EA and Chirdan LB, from Nigeria showed Hirschsprung's disease to be more common than intestinal atresias [4,10].

Congenital Pyloric Atresia (CPA) is a rare anomaly with an incidence of one in one lakh live births. They account for 1% of intestinal atresias and manifest as isolated defect or with associated malformations [11,12]. The most common anomaly that is associated with CPA in 50% cases is epidermolysis bullosa and the association is called Carmi's syndrome [13]. Epidermolysis bullosa is a group of hereditary skin disorder having blistering vesicular lesions with an incidence of 1 in 3 lakh live births [14,15]. Carmi's syndrome is very rare anomaly having genetic mutation disorder and associated with high mortality [14,16]. Although the present authors have diagnosed and operated one such case, the newborn developed sepsis postoperatively.

The embryological disorder causing duodenal atresia is considered as 'failure of recanalization' during 9-11 weeks of gestation, when other organs are developing [1,9]. So, the associated anomalies like Down syndrome, cardiac anomalies and malrotation are common. Down syndrome was associated in 23.5% of cases and malrotation in 12% of cases of duodenal atresias in the series. This is in contrast to late intrauterine vascular insult theory for jejuno-ileal atresias when other organs are developed. Jejunum was the most common site of atresia followed by duodenum. Out of two patients with apple-peel type of atresia, one patient had isolated jejunal duplication cyst. There occurs proximal jejunal atresia, large mesenteric defect and helical appearance of distal bowel around one perfusing vessel. Apple-peel atresia represents most severe form of ischaemic insult and its association with non-communicating

jejunal duplication cyst was first reported in this case [17]. The intrauterine vascular insult aetiology has been proposed for both the pathologies seen in this co-existence [18]. Out of two patients of colonic atresia detected during the study period, one patient also had a high Anorectal Malformation (ARM). Type II colonic atresia is also uncommon among all colonic atresias. High ARMs are associated with fistula to the urinary tract in 95% cases. So, the association of high ARM without fistula and Type II colonic atresia in one of our case is reported as a rare coexistence in literature [19].

Intestinal obstruction caused by Hirschsprung's disease is due to developmental anomaly affecting enteric nervous system. The distal bowel is devoid of normal peristalsis due to absence of ganglion cells, which are derivatives of neural crest cells. The aetiology may be multifactorial, having genetic background and possibly due to disorder of cranio-caudal migration of neural crest cells or during maturation process [20]. Delayed passage of meconium (>24 hours) and abdominal distention are common presenting features. Billious vomiting and visible bowel loops are seen in some cases. This typical clinical presentation and erect abdominal radiography showing dilated bowel loops, air-fluid levels and absence of gas shadow in pelvis were also observed in the present patients. Contrast enema study in Hirschsprung's disease will show dilated proximal bowel, a transition zone followed by distal aganglionic narrow segment and contrast retention in 24 hours delayed film. The contrast enema study is sensitive in 90% of newborns with Hirschsprung's disease [20]. Although this pathognomonic feature could be detected in variable percentage of cases in different studies [9], transition zone was detected in 80% of the present cases.

Rectal biopsy is gold standard for Hirschsprung's disease, but there is need for anaesthesia especially in centres where facilities for suction biopsy are unavailable. Full thickness rectal biopsy is not an easy procedure in newborns and there are chances of insufficient tissue. The present authors perform two stage management approach in most of the present cases. Laparotomy, levelling biopsy and sigmoid colostomy in left flank are done in newborn period. Biopsy will reveal absence of ganglion cells in myenteric and submucosal affected segment of bowel along with hypertrophied nerve trunks. Confirmed diagnosis of Hirschsprung's disease is made after

histopathological study using haematoxylin and eosin staining. When histopathological study by this conventional staining, does not reveal the pathology, in spite of strong clinical and radiological suspicion of Hirschsprung's disease, for specimens are subjected to calretinin immunohistochemical staining method. The present authors preferred Soave's endorectal pull-through as definitive procedure, which is performed around six months of age. Modified Duhamel and Swenson's procedures were done in selected cases.

Malrotation was the third most common pathology (11.1% cases) causing neonatal intestinal obstruction in the present series. Verma A et al., also found malrotation as third common cause (11.7% cases) in their series [8]. It is an important cause of intestinal obstruction in childhood and majority present during first month of life. Biliary vomiting is the predominant manifestation of malrotation in neonates. A scaphoid abdomen may be noted initially, but progressive distension may develop due to volvulus and bowel ischaemia [21]. Doppler ultrasonography will show inversion of superior mesenteric artery and vein position [22]. This feature was present in most of the present neonates with malrotation, making a pre-operative diagnosis. Meconium ileus causes intraluminal intestinal obstruction in newborns and is the earliest clinical sign of cystic fibrosis [1]. Erect abdominal radiography typically shows paucity or absence of air-fluid levels in spite of dilated bowel loops. A ground-glass or soap bubble type of picture may be seen due to mixing of swallowed air with tenacious meconium and calcification may be noted. Meconium ileus as a cause of intestinal obstruction has been found in 7.3%, 11% and 18.5% of neonates in few studies [4,7,8]. In the present study, meconium ileus was the fourth common cause, detected in 9.5% of cases.

Necrotizing Enterocolitis (NEC) may present as surgical emergency due to intestinal gangrene, perforation and peritonitis. It specifically affects preterm neonates and prognosis is not encouraging [23]. Rao LD et al., reported NEC in 3% of their cases of neonatal intestinal obstruction [7]. NEC with gangrene of ileum was found in 1.6% of the present cases during study period and required surgical intervention. Although the average duration of hospitalisation is not available from similar published studies, the present found it to be 8.5 days. The mortality rate from neonatal intestinal obstruction reported from different centres in developing countries varies from 16% to 26% [4,7,8,10]. However, the overall mortality in the present series was 11.1% and septicaemia was the most common cause.

LIMITATION

The limitation of the present study is that only the first stage operation performed during newborn period is discussed in patients requiring staged surgical procedure.

CONCLUSION

Intestinal atresia was found to be the most common cause of neonatal intestinal obstruction followed by Hirschsprung's disease and male newborns were more commonly affected. Majority of neonates present during first week of life due to an improved referral system from peripheral hospital. Septicaemia was the commonest cause of morbidity and mortality followed by wound infection. The overall outcome was good in the present study with a survival rate of 89%. Neonatal intestinal obstruction is one of the most common surgical emergencies in the present tertiary care hospital. Urgent resuscitation, diagnosis, surgical intervention and utmost utilization of available neonatal supporting system are key factors.

REFERENCES

- [1] Vinocur DN, Lee EY, Eisenberg RL. Neonatal Intestinal Obstruction. *AJR*. 2012; 198: W1-W10. DOI:10.2214/AJR.11.6931.
- [2] Wyllie R. Intestinal atresia, stenosis and malrotation. In: Kliegman RM, Behrman RE, Jenson HB, Stanton BF (editors) *Nelson's textbook of Paediatrics*. 8th ed. Vol. 2, Philadelphia: Saunders. Elsevier. 2008; 1558-62.
- [3] Nandi B, Mungongo C, Lakhoo KA. Comparison of neonatal surgical admissions between two linked surgical departments in Africa and Europe. *Pediatr Surg Int*. 2008;24(8): 939-42. DOI:10.1007/s00383-008-21777-x.
- [4] Saha AK, Ali MB, Biswas SK, Sharif HMZ, Azim A. Neonatal intestinal obstruction: patterns, problems and outcome. *Bang Med J (Khulna)* 2012; 45:6-10. DOI:https://doi.org/10.3329/bmj.k.v45i1-2.13638
- [5] Seth A, Chanchlani R, Rakhonde AK. Neonatal gastrointestinal emergencies in a tertiary care center in Bhopal, India: A prospective study. *IJSS Journal of Surgery*. 2015; 1(5): 1-4. DOI:10.17354/SUR/2015/29
- [6] Talari VK, Sipala SK. A clinical study of neonatal intestinal obstruction. *IOSR-JDMS*. 2017;16(8): 8-14. DOI:10.9790/0853-1608030814.
- [7] Rao LD, Rao KVJ, Kameswari K. Neonatal Intestinal Obstruction. *IOSR-JDMS*. 2018;17(2):50-53. DOI:10.9790/0853-1702165053.
- [8] Verma A, Ranjan KN, Yadav R. Neonatal Intestinal Obstruction: A 15 year experience in a tertiary care hospital. *J Clin Diagn Res*. 2016; 10(2): SC10-SC13. DOI:10.7860/JCDR/2016/17204.7268.
- [9] Pathak M, Saxena R, Sinha A, Singh V. Hirschsprung's disease and neonatal intestinal obstruction: Where does it lie in the spectrum? *J Clin Neonatol* 2018;7:231-36. DOI:10.4103/jcn.JCN_48_18
- [10] Ameh EA, Chirdan LB. Neonatal intestinal obstruction in Zaria, Nigeria. *East Afr Med J*. 2000; 77(9):510-13.
- [11] Muller M, Morger R, Engert J. Pyloric atresia: report of two cases and review of literature. *Pediatr Surg Int*. 1990; 5:276-79. DOI: https://doi.org/10.1007/BF00169670
- [12] Moore CMC. Congenital gastric outlet obstruction. *J Pediatr Surg*. 1989; 24: 1241-46. DOI: https://doi.org/10.1016/S0022-3468(89)80559-7
- [13] Carmi R, Sofer S, Karphus M, Ben-Yakar Y, Mahler D, Zirkin H, et al. Aplasia cutis congenital in two sibs discordant for pyloric atresia. *Am J Med Genet*. 1982; 11:319-28. DOI: https://doi.org/10.1002/ajmg.1320110308
- [14] Gupta R, Soni V, Mathur P, Goyal RB. Congenital pyloric atresia and associated anomalies: A case series. *J Neonat Surg* 2013; 2(4):40.

- [15] Hayashi AH, Galliani CA, Gillis DA. Congenital pyloric atresia and junctional epidermolysis bullosa: a report of long term survival and review of the literature. *J Pediatr Surg.* 1991;26:1341-45.
- [16] Bawazir Osama A, Al-Salem Ahmed H. Congenital pyloric atresia: clinical features, diagnosis, associated anomalies, management and outcome. *Ann Pediatr Surg.* 2017;13(4): 188-93. DOI: 10.1097/01.XPS.0000521014.13423.8b.
- [17] Tripathy PK, Pattnaik K, Jena PK, Mohanty HK. Apple-peel intestinal atresia along with isolated jejunal duplication cyst in a newborn -An extremely rare case report and brief review. *J Clin Diagn Res.* 2017; 11(6):SD01-02. DOI: 10.7860/JCDR/2017/26900.10123.
- [18] Favara BE, Franciosi RA, Akers DR. Enteric duplications. Thirty seven cases: a vascular theory of pathogenesis. *Am J Dis Child.* 1971; 122: 501-06.
- [19] Tripathy PK, Jena PK. Type II colonic atresia and high anorectal malformation: A rare coexistence and literature review. *Indian J Neonatal Med and Res.* 2017; 5(3): PC04-PC06. DOI: 10.7860/IJNMR/2017/29190.2213.
- [20] Langer JC. Hirschsprung disease. In: Holcomb III GW, Murphy JP, Ostlie DJ, Editors. *Ashcraft's Pediatric Surgery.* 6th ed. Philadelphia: Elsevier Saunders; 2014. Pg 474-91.
- [21] Ford EG, Senac MO, Srikanth MS. Malrotation of intestine in children. *Ann Surg.* 1992; 215(2): 172-78.
- [22] Zhang W, Sun H, Luo F. The efficiency of sonography in diagnosing volvulus in neonates with suspected intestinal malrotation. *Medicine(Baltimore).* 2017; 96(42): e8287. DOI: org/10.1097/MD.0000000000008287.
- [23] Tripathy PK, Nanda R. Management modalities for necrotising enterocolitis: Targeting Toll like receptors. *AABS* 2016; 3(1): R1-R5.

AUTHOR(S):

1. Laxmikanta Mohapatra
2. Prasanta Kumar Tripathy
3. Pradeep Kumar Jena
4. Hiranya Kishor Mohanty

PARTICULARS OF CONTRIBUTORS:

1. Postgraduate Student, Department of Paediatric Surgery, SVPPGIP, SCB Medical College, Cuttack, Odisha, India.
2. Assistant Professor, Department of Paediatric Surgery, SVPPGIP, SCB Medical College, Cuttack, Odisha, India.
3. Professor, Department of Paediatric Surgery, SVPPGIP, SCB Medical College, Cuttack, Odisha, India.

4. Professor, Department of Paediatric Surgery, SVPPGIP, SCB Medical College, Cuttack, Odisha, India.

NAME, ADDRESS, E-MAIL ID OF THE CORRESPONDING AUTHOR:

Dr. Prasanta Kumar Tripathy,
Assistant Professor, Department of Pediatric Surgery,
SVPPGIP, Cuttack, Odisha, India.
E-mail: drpktripathy555@gmail.com

FINANCIAL OR OTHER COMPETING INTERESTS:

None.

Date of Publishing: **Apr 01, 2019**