

Candida Funisitis: Common Organism with Uncommon Presentation

MONICA SURYAVANSHI, RATNAPRABHA GHODKE, PRAGATI SATHE, MANJUSHA RAY, ANNA PURNA C TAWARE

ABSTRACT

Funisitis is the inflammation of umbilical cord while, chorioamnionitis is inflammation of placental membranes i.e., chorion and amnion. The mucus plug in lower genital tract acts as barrier during pregnancy. The intramniotic entry of *Candida* can be via haematogenous or penetration of intact membranes. Presence of intrauterine contraceptive device and prolonged rupture of membranes are proven risk factors for candidal infection. The prevalence of candidal vaginitis is high but involvement of placenta and subsequent foetal involvement is rare.

Good placental examination especially, cords and membranes can clinch the diagnosis and can help in initiating

investigations in the newborn for congenital candidiasis.

We here presenting a case of 23-year-old fourth gravida female with previous two spontaneous abortions and history of preterm labour during current pregnancy came with complains of leaking per vagina at 33.6 weeks. The placenta sent for histopathological examination revealed presence of tiny yellowish white tubercles on umbilical cord especially near the site of insertion to placental disc. Microscopic examination of section of umbilical cord revealed presence of typical subamniotic neutrophilic micro abscesses along with candidal yeast as well as pseudohyphae forms, the latter being highlighted by special stains for fungi.

CASE REPORT

A 23-year-old fourth gravida female patient had a history of two spontaneous abortions and one living healthy female child born of a full term normal vaginal delivery. During her current pregnancy, she was admitted to the hospital at 29 weeks of gestation in view of preterm labour and received two doses of injectable bethasol and injectable jectose and discharged from hospital after clinical stabilisation. At 33.6 weeks, she came with complain of leaking per vagina since one day, per vaginal examination revealed 2.5 cm dilated and 30-40% effaced internal os of cervix.

Laboratory investigations showed total leucocyte count of 20,900/ μ L with 78% of polymorphs. Emergency Lower Segment Caesarean Section (LSCS) was performed in view of premature rupture of membranes with respiratory distress in fetus. A 2.24 Kg male child was delivered with APGAR score of 9/10 at one and five minutes after birth. There were no signs and symptoms of respiratory distress, skin rash or external congenital anomaly.

Laboratory investigations of the neonate revealed a total leucocytes count of 29,500/ μ L with differential count of

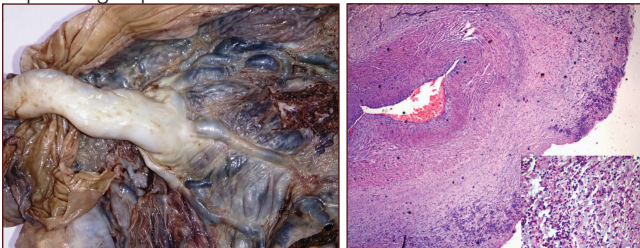
Keywords: Candidiasis, Chorioamnionitis, Placenta, Preterm

myelocytes 5%, metamyelocytes 18%, band forms 10%, polymorphs 36%, lymphocytes 26%, eosinophils 2%, monocytes 3%, along with presence of toxic granules within polymorphs and shift to left. C-reactive protein value was 6.61 mg/L (normal range 2-5 mg/L). The blood culture was negative for bacterial infection. Two dimensional echocardiography of the baby showed dextrocardia with heart axis of 60° and a small ostium secundum atrial septal defect, multiple small ventricular septal defects and a tiny patent ductus arteriosus. Baby was transferred to neonatal intensive care unit in view of leucocytosis. Neonate was started on empiric antibiotic therapy with Inj. ampicillin and amikacin. Antifungal agents were not started as the parents took discharge against the medical advice.

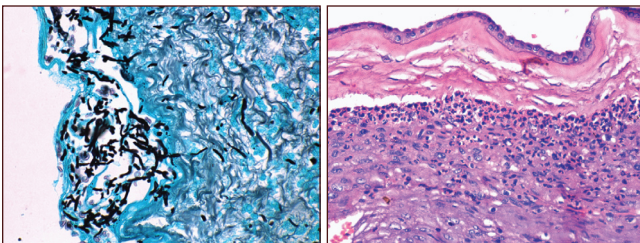
The placenta was sent for histopathological examination. The formalin fixed placenta with attached umbilical cord weighed 550 gm. The umbilical cord was centrally attached to the placental disc and was 18 cm long and 1 cm in diameter. Two umbilical arteries and one umbilical vein identified grossly. Multiple well circumscribed yellowish white raised lesions 1-2 mm in size were present on external surface of umbilical cord, more near

the cord insertion. The placental disc measured 16×13×1 cm. The membranes were grossly unremarkable. Maternal surface of placental disc showed well formed cotyledons and on serial sectioning the cut surface was unremarkable. Foetal surface showed two grey white pale firm areas measuring 2×1×0.5 cm and 1×0.8×0.1 cm respectively.

Microscopic examination of the umbilical cord revealed multiple sub-amniotic micro abscesses. They were composed of necrotic debris admixed with neutrophils and fungi with morphology of budding yeast as well as pseudohyphae. The special stains like Gomori's Methenamine-Silver (GMS) and Periodic Acid Schiff (PAS) stain highlighted the *Candida*. The amnion and chorion showed diffuse moderate chorioamnionitis. The placenta showed third trimester villi with focal intervillous and intravillous fibrin deposition corresponding to the firm areas seen on gross examination. There were no villitis or organisms demonstrated in the membranes or in the placenta. A diagnosis of candida funisitis and chorioamnionitis was given [Table/Fig-1-4]. We report a case of candida funisitis with neonate showing signs of impending sepsis and associated dextrocardia.



[Table/Fig-1]: Candida funisitis-Umbilical cord grossly showing typical yellow white tubercles (Black arrow). **[Table/Fig-2]:** Characteristic sub amniotic wedge shaped micro abscesses (H&E, 40X); high power view 400X (inset).



[Table/Fig-3]: Gomori's Methenamine Silver stain highlighting the yeast forms as well as pseudohyphae of *Candida* species (40X).

[Table/Fig-4]: Acute Grade 2 chorioamnionitis, arrow (H&E, 100X).

DISCUSSION

The prevalence of candidal vulvo vaginitis is high and ranges between 10-35% in pregnant women [1]. However, placental involvement as well as antenatal or congenital candidal infection in foetus is rare. Chorioamnionitis which is observed in less than 1% pregnant women is considered to be one of the mechanisms for foetal infection to develop [2]. The most frequent placental pathology is acute chorioamnionitis and it represents the part of the "amniotic fluid infection syndrome" [3]. Candida funisitis and chorioamnionitis have also been observed in the absence

of congenital infection [4]. The inflammatory process involving the umbilical cord is referred as funisitis [3]. The inflammatory process affecting the chorion and amnion is termed as acute chorioamnionitis [5]. The chorioamnionitis is staged on the basis of anatomical location and the intensity of acute inflammatory response defines the grade [3]. Decidua in the supracervical region is the first site of localisation of micro-organisms in case of ascending infection. During pregnancy, the mucus plug present in lower genital tract acts as anatomic as well as functional barrier for the ascending infection [6,7]. *Candida* species is able to penetrate 'intact' membranes. However, the pathogenesis is not understood. The portal of entry for the *Candida* can be haematogenous, direct extension, via intact membranes or ascending infection due to prolonged rupture of membranes [8]. Alteration of female genital tract bacterial flora along with increased colonisation of yeast in vagina has been noted in presence of intrauterine foreign devices [8]. Ascending maternal cervicovaginal candidiasis gives rise to congenital candidiasis either cutaneous or systemic. Prolonged rupture of membranes for more than 48 hours significantly increases the risk of foetal candidiasis [8]. Less than 1% women having vaginal candidiasis develops chorioamnionitis hence, placental infection is rare compared to vaginal candidiasis [2]. In present case mother had history of leaking per vagina for more than 12 hours leading to prolonged premature rupture of membranes causing ascending infection. Umbilical cord is most commonly involved structure in *Candida* placentitis followed by placental chorionic surface, intervillous space and rarely chorionic villi. The microbial invasion of amniotic cavity increases the risk of neonatal sepsis being more in preterm neonates. Foetal congenital candidal infection is even rarer; less than 100 cases have been reported in the medical literature [2]. *Candida* species can be demonstrated from foetal surface of 0.8% of placentas. Premature infants are more prone for congenital systemic infection [4]. Thorough clinical examination and laboratory investigation including culture of urine, blood and cerebrospinal fluid is of diagnostic help but, a negative result doesn't rule out systemic infection [4,7]. In our case CSF and urine culture was not performed.

Qureshi F et al., reported 32 cases of candida funisitis collected over 13 years from six institutions [9]. The mean age of mother in their study was 28 years, comparable to our patient. Whyte RK et al., observed previous spontaneous abortions in 5 out of 18 cases [7], our patient also had history of two previous spontaneous abortions. Our case had preterm premature rupture of membranes for 24 hours and similar finding was observed in other case studies as well [7,9,10]. Mother's urine and blood culture were positive in case studied by Oberhauser S et al., on the other hand cervical culture was positive amongst one of the 30 cases of necrotizing funisitis study by Qureshi F et al., [9,10]. Blood as well as placental tissue culture were not performed in our case.

Presence of yellowish white tubercles on umbilical cord was found to be characteristic of candida funisitis [7,9]. On microscopic examination, the umbilical cord revealed multiple subamniotic micro abscesses composed of necro - inflammatory exudate as well as fungal elements, our findings are in conformity with other studies [7,9,10]. Absence of decidual plate or chorionic villi involvement was in concordance with other studies [7,9]. Case reported by Schirar DA et al., demonstrated the *Candida* species in the vascular lumina of chorionic plate in placenta weighing 650 gm [4]. In our report antenatal candidal infection was not diagnosed in mother as well as neonate did not show any clinical signs of congenital candidal infection. Hence, the targeted therapy against *Candida* species couldn't be initiated. Neonate was started on empiric antibiotic treatment with injectable ampicillin and amikacin. In study done by Oberhauser S et al., fluconazole was added to treatment regime of mother after culture positivity and neonate was treated sequentially with antifungal drugs Amphotericin B and later on shifted to micafungin [10]. Treatment with amphotericin B in mother showing blood culture positivity for *Candida* species has been reported by Dean JL et al., [11]. Shalev E et al., reported a case of preterm premature rupture of membranes treated with intrauterine amphotericin B instillation [12]. The relationship between dextrocardia and candida funisitis as seen in our case could not be established and has not been reported in literature.

CONCLUSION

Careful examination of the cord and membranes in the delivery room facilitates early diagnosis as candida funisitis has typical gross appearance. Microscopic examination and special fungal stains help in confirming the diagnosis. Thus, good placental examination can clinch the diagnosis and can help in initiating investigations in the neonate for congenital candidiasis.

REFERENCES

- [1] Diana A, Epiney M, Ecoffey M, Pfister RE. "White dots on the placenta and red dots on the baby": congenital cutaneous candidiasis- a rare disease of the neonate. *Acta Paediatr.* 2004; 93(7):996-99.
- [2] Aldana-Valenzuela C, Morales-Marquec M, Castellanos-Martínez J, Deanda-Gómez M. Congenital candidiasis: a rare and unpredictable disease. *J Perinatol.* 2005;25:680-82.
- [3] Kim CJ, Romero R, Chaemsaitong P, Chaiyasit N, Yoon BH, Kim YM. Acute chorioamnionitis and funisitis: definition, pathologic features, and clinical significance. *Am J Obstet Gynecol.* 2015;213(4 Suppl):S29-52.
- [4] Schwartz DA, Reef S. *Candida albicans* placentitis and funisitis: early diagnosis of congenital candidemia by histopathologic examination of umbilical cord vessels. *Pediatr Infect Dis J.* 1990;9(9):661-65.
- [5] Redline RW, Faye-Petersen O, Heller D, Qureshi F, Savell V, Vogler C, et al. Amniotic infection syndrome: nosology and reproducibility of placental reaction patterns. *Pediatr Dev Pathol.* 2003;6(5):435-48.
- [6] Hein M, Helmig RB, Schönheyder HC, Ganz T, Ulbjerg N. An in vitro study of antibacterial properties of the cervical mucus plug in pregnancy. *Am J Obstet Gynecol.* 2001;185(3):586-92.
- [7] Whyte RK, Hussain Z. Antenatal infections with *Candida* species. *Arch Dis Child.* 1982;57(7):528-35.
- [8] Roqué H, Abdelhak Y, Young BK. Intra amniotic candidiasis. Case report and meta-analysis of 54 cases. *J Perinat Med.* 1999;27(4):253-62.
- [9] Qureshi F, Jacques SM, Bendon RW, Faye-Peterson OM, Heifetz SA, Redline R, et al. *Candida* funisitis: a clinicopathologic study of 32 cases. *Pediatr Dev Pathol.* 1998;1(2):118-24.
- [10] Oberhauser S, Böhm S, Niederer A, Rogdo B. Congenital cutaneous candidiasis and candidemia in a preterm infant: A case report. *Case Reports in Clinical Pathology.* 2017;4(1):68.
- [11] Dean JL, Wolf JE, Ranzini AC, Laughlin MA. Use of amphotericin B during pregnancy: case report and review. *Clin Infect Dis.* 1994;18(3):364-68.
- [12] Shalev E, Battino S, Romano S, Blondhaim O, Ben-Ami M. Intraamniotic infection with *Candida albicans* successfully treated with transcervical amnioinfusion of amphotericin. *Am J Obstet Gynecol.* 1994;170(5 Pt 1):1271-72.

AUTHOR(S):

1. Dr. Monica Suryavanshi
2. Dr. Ratnaprabha Ghodke
3. Dr. Pragati Sathe
4. Dr. Manjusha Ray
5. Dr. Annapurna C Taware

PARTICULARS OF CONTRIBUTORS:

1. Fellow, Department of Paediatrics Pathology, Seth GS Medical College and KEM Hospital, Mumbai, Maharashtra, India.
2. Assistant Professor, Department of Pathology, Seth GS Medical College and KEM Hospital, Mumbai, Maharashtra, India.
3. Associate Professor, Department of Pathology, Seth GS Medical College and KEM Hospital, Mumbai, Maharashtra, India.

4. Fellow, Department of Paediatrics Pathology, Seth GS Medical College and KEM Hospital, Mumbai, Maharashtra, India.
5. Associate Professor, Department of Pathology, Seth GS Medical College and KEM Hospital, Mumbai, Maharashtra, India.

NAME, ADDRESS, E-MAIL ID OF THE CORRESPONDING AUTHOR:

Dr. Monica Suryavanshi,
C-9/404, Vedant Complex, Vartak Nagar,
Mumbai-400606, Maharashtra, India.
E-mail: monicasuryavanshi@gmail.com

FINANCIAL OR OTHER COMPETING INTERESTS:

None.

Date of Publishing: Jan 01, 2018