

# Goldston Syndrome – A Rare Case Report

NAGABHUSHAN BM, PAVITRA N ARALIKATTI, VIJAYALAXMI GAGANDEEP

## ABSTRACT

Goldston syndrome is a condition where Dandy-Walker malformation of brain is associated with polycystic kidneys. Newborn on day one came to Neonatal Intensive Care Unit for evaluation of hydrocephalus. Fetal cranial ultrasound revealed deficient vermis with

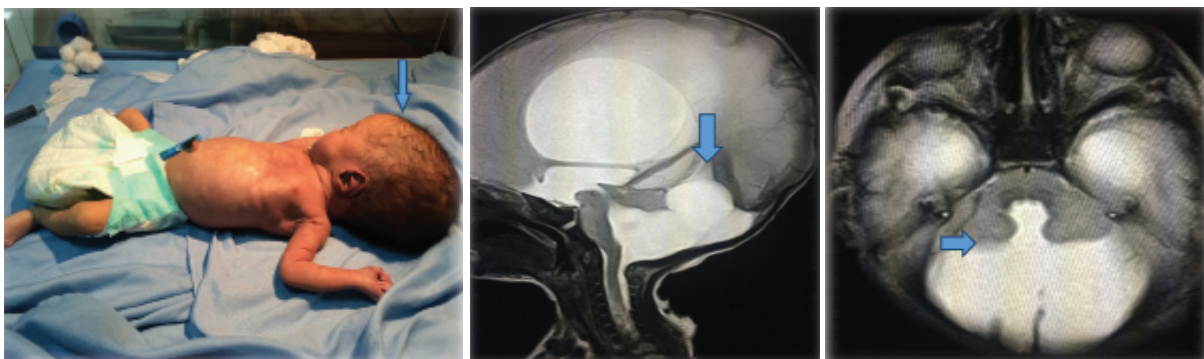
a posterior fossa cyst communicating with 4<sup>th</sup> ventricle suggestive of Dandy-Walker malformation. Ultrasound abdomen and pelvis showed echogenic enlarged kidneys containing small cysts. The diagnosis of Goldston syndrome was suggested. Dandy-Walker malformation was confirmed by MRI brain.

**Keywords:** Antenatal ultrasound scan, Hydrocephalus, Renal cysts.

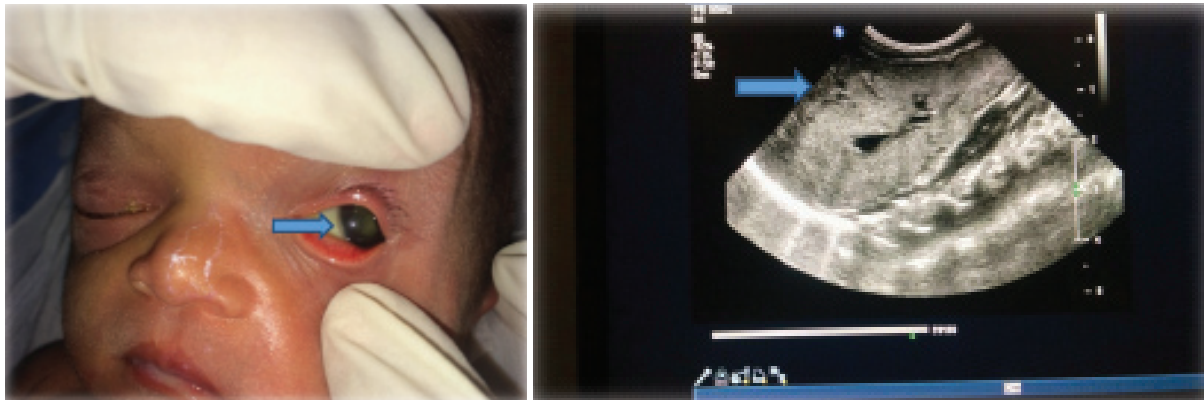
## CASE REPORT

A case of female newborn came immediately after birth to Neonatal Intensive Care Unit for evaluation of hydrocephalus. It was an unregistered pregnancy with no regular antenatal visits for check up and no documented antenatal ultrasound scans. Mother came in active labor to Bowring and Lady Curzon Hospital, Bangalore. She delivered immediately after admission. No ultrasound abdomen was done. Clinically, cervix was fully dilated and fully effaced, baby's head was at +2 station. It was a full term normal vaginal delivery with normal birth weight of 2.5 kg, baby cried immediately after birth with normal APGAR scores. The newborn had macrocephaly with head circumference measuring 39 cm [Table/Fig-1]. Post-natal ultrasound scan was obtained on day 2 of life to evaluate the cause for macrocephaly. Ultrasound examination of brain showed absence of vermis with posterior fossa cyst communicating with fourth ventricle, same confirmed by MRI brain [Table/Fig-2,3]. There was also bilateral congenital cataract present, asymmetrical,

had spokes from their outer edge [Table/Fig-4]. No midline defects noted. Ultrasound abdomen revealed both kidneys having echogenic parenchyma with tiny cysts scattered in cortex [Table/Fig-5]. No evidence of hepatic fibrosis or portal system abnormalities noted on ultrasound abdomen. 2D ECHO on day 4 showed Atrial septal defect and Ventricular septal defect with normal biventricular function. Laboratory findings showed CRP positive >30 mg/dl, Total counts of 23000 cells/mm<sup>3</sup> with neutrophil predominance of 80%, mild thrombocytopenia of 0.56 lacs/l. Renal function tests were deranged with creatinine of 2 mg/dl Blood culture was sent. The neonatal liver function test and thyroid function tests were normal. Fetal blood chromosome karyotyping sent (reports awaited). The child developed sepsis, started on antibiotics injection Ceftriaxone and injection Amikacin. Patient did not show any improvement and succumbed to death on day 7. Parents denied for post mortem investigations to prove the diagnosis.



**[Table/Fig-1]:** Newborn with macrocephaly. **[Table/Fig-2]:** MRI brain showing enlargement of posterior fossa of brain. **[Table/Fig-3]:** MRI of brain showing dilated fourth ventricle.



**[Table/Fig-4]:** Showing cataract. **[Table/Fig-5]:** USG abdomen showing renal cysts.

## DISCUSSION

Dandy-Walker malformation is characterized by triad of cerebellar vermis agenesis with posterior fossa cyst communicating with the fourth ventricle and enlargement of posterior fossa. It is commonly associated with neurological abnormalities. Other systems like cardiopulmonary, skeletal, ocular, genitourinary and gastrointestinal system can also get associated and present with various severity. Goldston syndrome is a condition where Dandy-Walker malformation of brain is associated with polycystic kidneys [1,2]. It was first described by Goldston in 1963 and is very rare disorder with few cases reported in world. Few cases have been detected in ante natal ultrasound scans. In this case report, the case of Goldston syndrome was diagnosed on postnatal ultrasound and MRI during evaluation of hydrocephalus.

The association of CNS abnormalities with renal system involvement is reported as a rare entity. The syndrome that had been described of this combination was Meckel syndrome type 7, autosomal recessive disorder based on classic phenotypic triad of cystic renal disease, central nervous system abnormalities and hepatic abnormalities. However, Meckel syndrome constitutes a wide variety of anomalies like ocular, cleft palate, polydactyl, cardiac anomalies, pseudo hermaphroditism and other malformations which are mostly incompatible with life and on prenatal diagnosis termination of pregnancy is advised. Miranda syndrome (cerebrohepatorenal syndrome) associated with Dandy-Walker malformation, congenital hepatic fibrosis and cystic dysplastic renal lesions. Miranda and Goldston syndrome seems to be milder variant of Meckel's syndrome with fewer congenital anomalies involving only cerebral, renal and hepatic systems [3,4]. The Goldston who reported three siblings with diffuse cystic renal dysplasia but no hepatic fibrosis, two cases described by him also had Dandy-Walker malformation [5-7].

Gloeb et al., reported a 17-week old fetus with marked dilation of fourth ventricle and cystic renal dysplasia on ante natal ultrasound scan. Postmortem examination

revealed evidence microscopic lesions in the liver and considered this to be a case of Miranda syndrome [8-10]. Karmous-Benailly H et al., described 'Mekel like syndrome' consisting of Dandy-Walker malformation, cystic kidneys, and hepatic fibrosis without bile duct proliferation [10].

## CONCLUSION

The diagnosis of Dandy-Walker malformation and enlarged echogenic kidneys can be detected during routine antenatal anomaly scans. Thus, efforts to pick up such syndromes which are incompatible with life should be meticulous and stringent. Furthermore, antenatal chromosomal and karyotyping studies should be done to further enlighten the scenario. Presence of Dandy-Walker malformation on antenatal scan should necessitate a search for other associated extra cranial malformations particularly in genitourinary, cardiac, skeletal and gastrointestinal system.

## REFERENCES

- [1] Gulcan YH, Duman N, Kumral A, Sagol O, Lebe B, Kavukcu S, et al. Goldston syndrome: report of a case. *Genet Couns.* 2001; 12: 263-67.
- [2] Bernstein J, Brough AJ, Mc Adams AJ. The renal lesion in syndromes of multiple congenital malformations. cerebrohepatorenal syndrome; jeune asphyxiating thoracic dystrophy; tuberous sclerosis; Meckel syndrome. *Birth Defects Orig Artic Ser.* 1974;10: 35-43.
- [3] Kudo M, Tamura K, Fuse Y. Cystic dysplastic kidneys associated with Dandy-Walker malformation and congenital hepatic fibrosis. Report of two cases. *Am J Clin Pathol.* 1985; 84:459-63.
- [4] Goldston AS, Burke EC, D'Agostino A, Maccaughey WT. neonatal polycystic kidney with brain defect. *Am J Dis Child.* 1963; 106: 484-88.
- [5] Moerman P, Pauwells P, Vandenberghe K, Lauweryns JM, Fr yns JP. Goldston syndrome reconsidered. *Genet couns* 1993; 4:97-102.
- [6] Walpole IR, Goldblatt J, Hockey A, Knowles S. Dandy-Walker malformation variant, cystic dysplastic kidneys, and hepatic fibrosis: a distinct entity or Meckel syndrome? *Am J Med Genet.* 1991;39:294-98.
- [7] Menon R, Nadkarni T, Desai K, Goel A. Dandy-Walker malformation associated with polycystic kidneys: Goldston syndrome revisited. *J Clin Neuro sci.* 2006;13:875-77. Epub 2006 Aug 23.

- [8] Hussain Z, Masroor I, Haider Q, Alam T. Goldston syndrome case report. *Journal of the college of physicians and surgeons Pakistan*. 2011;21(4):242-44.
- [9] Gloeb DJ, Valdes-Dapena M, Salman FO, Sullivan MJ, Quetel TA. The Goldston syndrome: report of a case. *Pediatrpathol*. 1989; 9:337-43.
- [10] Karmous-Benailly H, Martinovic J, Gubler MC, Sirot Y, Clech L, Ozilou C, et al. Antenatal presentation of Bardet-Biedl syndrome may mimic Meckel syndrome. *Am J Hum Genet*. 2005;76:493-504.

**AUTHOR(S):**

1. Dr. Nagabhushan B M
2. Dr. Pavitra N Aralikatti
3. Dr. Vijayalaxmi Gagandeep

**PARTICULARS OF CONTRIBUTORS:**

1. Post Graduate, Department of Paediatrics, Bangalore Medical College & Research Institute, Bangalore, Karnataka, India.
2. Post Graduate, Department of Paediatrics, Bangalore Medical College & Research Institute, Bangalore, Karnataka, India.
3. Assistant Professor, Department of Paediatrics, Bangalore Medical College & Research Institute, Bangalore, Karnataka, India.

**NAME, ADDRESS, E-MAIL ID OF THE CORRESPONDING AUTHOR:**

Dr. Nagabhushan B M,  
Post Graduate, Department of Paediatrics,  
Vani Vilas Hospital, BMC&RI Fort, Near KR Market,  
Bangalore-560002, Karnataka, India.  
E-mail: Nagbhushan\_bm@yahoo.com

**FINANCIAL OR OTHER COMPETING INTERESTS:**

None.

Date of Publishing: Oct 01, 2016