

# Acute Neonatal Suppurative Parotitis with Facial Palsy and Pneumonia

RAHUL MANSING KADAM, VSV PRASAD, SUDHA BODA

## ABSTRACT

Acute Neonatal Suppurative Parotitis (NSP) is a rare infection in neonates. To our knowledge, only few cases are reported in English literature with hardly any case from India. The most

common causative organism is *Staphylococcus aureus*. Here, we report a rare case of acute NSP with late onset sepsis and complications such as facial palsy and pneumonia due to *Pseudomonas aeruginosa* infection in a term neonate.

**Keywords:** Incision and drainage, Intravenous antibiotics, Pus culture, Swelling, Ultrasonography

## CASE REPORT

A 9 days old, term, female neonate was admitted to our hospital with complaints of fever, poor feeding, swelling in the right pre-auricular region and respiratory distress.

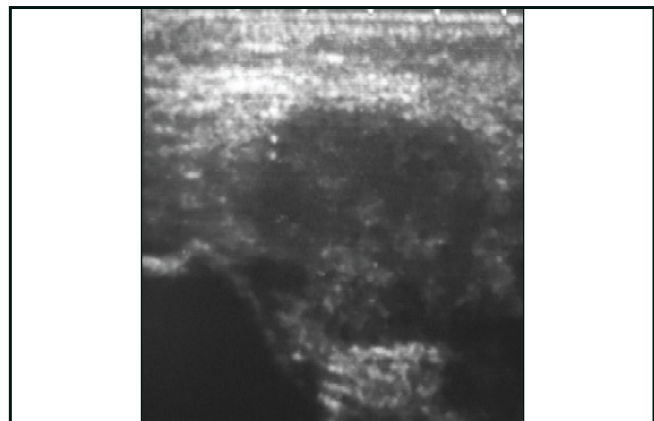
She was born by cesarean section, with birth weight of 2.6 kg. Antenatal period was uneventful. She was said to be cried immediately after birth and was exclusively breastfed. However, on day 4 of life, she was noticed to have fever and there was a swelling noted in right pre-auricular region. Subsequently, she was noticed to have poor feeding and decreased activity. With these complaints, she was admitted elsewhere and was treated with intravenous antibiotics and fluids. She developed respiratory distress on day 8 of life and was started on oxygen supplementation. She was referred to our hospital for further management.

At admission she was lethargic, had respiratory distress with room air saturation of 85%. Examination revealed 2.5 x 2.5 cm, erythematous, tender, fluctuant swelling in the right preauricular region with local rise of temperature. Mouth was deviating to left side while crying. There was exudation of pus from Stensen's duct on pressing the swelling. Re-appraisal of history did not reveal any breast abscess in mother or any trauma to face of the neonate. The possibilities considered were cellulitis, parotid abscess, sialolithiasis and late onset sepsis.

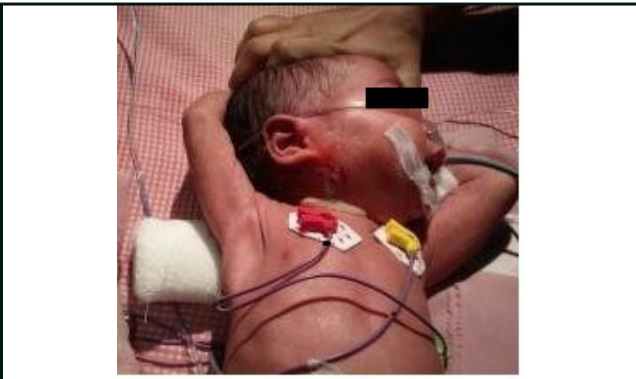She was started on intravenous fluids and intravenous antibiotics (vancomycin and meropenem) following performing workup for sepsis. Her complete blood count revealed thrombocytopenia. Her C-reactive protein was elevated, 56 mg/dl. Her chest skiagram revealed bilateral lung infiltrates,

consistent with pneumonia. Ultrasonography of the parotid glands demonstrated a hypoechoic area diffusely involving right parotid gland compatible with parotid abscess, [Table/Fig-1] with thrombosis of retromandibular vein.

Incision and drainage of the abscess was performed and around 15ml of greenish yellow pus was drained [Table/Fig-2]. Pus culture grew *Pseudomonas aeruginosa*, hence vancomycin was stopped and meropenem was continued as per sensitivity pattern. Her blood culture was sterile. Cerebrospinal fluid examination was performed to rule out meningitis and was unremarkable. As the ultrasound of parotid gland had shown right retromandibular vein thrombosis, CT-angiogram of head and neck vessels was performed to rule out intracranial extension of thrombus and was unremarkable. Right facial palsy recovered after drainage of the parotid abscess. She required



**[Table/Fig-1]:** Sonogram of right parotid gland shows diffuse hypoechoic area.



**[Table/Fig-2]:** Clinical photograph depicting a parotid abscess with exudation of pus from incision site.

oxygen supplementation for 2 days after which she could be weaned to room air. Her thrombocytopenia improved over the time. Initially, she was commenced on oro-gastric tube feeds, oral feeds were initiated after resolution of respiratory distress and she was started on breast feeds on day 7 of hospital stay. IV Meropenem was given for a total duration of 14 days.

At discharge her surgical wound had healed well. Her clinical physical examination was within normal limits. She is on regular follow-up and doing well with normal growth parameters and development.

## DISCUSSION

Our index case was a term, exclusively breast fed baby and she did not have any risk factors for sepsis, yet developed a parotid abscess and had complications like pneumonia, culture negative sepsis and facial palsy. Hence, high index of suspicion is required for diagnosis.

Acute NSP is a rare entity in neonates [1]. Incidence is 13.8 per 10,000 admissions [2] while prevalence is 3.8 per 10,000 admissions [1]. A study by Spiegel et al., identified only 32 cases in English literature between 1970 and 2004 [1]. Male to female incidence is 3:1 [1]. NSP is more common in preterm babies [3,4]. Parotid gland is the most affected gland of all salivary glands. Causes of parotid swelling are suppuration, trauma, hemangiomas, lymphangiomas, mumps, tumors and any blockage in Stensen's duct [5,6]. Other risk factors are prolonged gavage feeds [4], immunosuppression [1,7] and dehydration leading to stasis of secretions and sialadenitis. Use of chin strap during CPAP therapy might lead to stasis of secretions and suppuration [8]. Causative organisms of parotid abscess are predominantly *Staphylococcus aureus* which accounts for almost 55% of cases [3,5,9] followed by other organisms like *Staphylococcus viridians*, *Streptococcus agalactiae*, *E coli*, *Pseudomonas*, *Klebsiella*, *N. catarrhalis*, very rarely *Bacteroides* and *Fusobacterium*. Infection commonly spreads from oral flora ascending via stensen's duct into the

gland, hematogenous spread is also reported [3].

The diagnosis is always clinical. The three diagnostic criteria are parotid swelling, purulent exudation from Stensen's duct and growth of organism in pus culture. Other systemic symptoms are fever, irritability and poor oral intake. The management of NSP involves work up for sepsis including blood culture, ultrasound of parotid gland and Pediatric surgeon or Otolaryngologist consultation. Adequate rehydration and oral hygiene maintenance should be ensured. Mainstay of treatment is appropriate intravenous antimicrobial therapy [9]. Early antibiotic treatment reduces the need for surgery with almost 80% of the patients improve without any surgical intervention. Empirical intravenous antibiotics having gram positive and anaerobic cover should be started and used for a duration of 7 to 10 days [1,3]. If the neonate is not responding to antimicrobial therapy or if associated with complications then surgical intervention like needle aspiration or incision and drainage should be performed. Sepsis, shock and pneumonia must be appropriately treated, if present. Our patient required incision and drainage of the abscess and intravenous antibiotics for 14 days. Complications are bacteremia, sepsis [10], salivary fistula, facial palsy [4], mediastinitis, extension of infection into external ear, osteomyelitis of mandible and thrombophlebitis of jugular vein. Our neonate had right facial palsy at admission which recovered after drainage of the abscess.

## CONCLUSION

Although, NSP is rare in neonates, it should be suspected in neonates with facial swelling and sepsis. Complications should be anticipated, appropriately investigated and treated with adequate hydration, antimicrobial therapy and surgical drainage if necessary. As there is change in nature of bacterial isolates, we recommend culture driven antimicrobial therapy. Early diagnosis and appropriate intravenous antibiotics might prevent serious complications.

## REFERENCES

- [1] Spiegel R, Miron D, Sakran W, Horovitz Y. Acute neonatal suppurative parotitis: case reports and review. *Pediatr Infect Dis J*. 2004;23(1):76-78.
- [2] Sabatino G, Verrotti A, De Martino M, Fusilli P, Pallotta R, Chiarelli F, et al. Neonatal suppurative parotitis: A study of five cases. *European Journal of Pediatrics*. 1999;158(4): 312-14.
- [3] Schwab J, Baroody F. Neonatal suppurative parotitis: a case report. *Clinical Pediatrics*. 2003;42(6):565-66.
- [4] Chevalier J, Jadcherla SR. Parotid swelling in a premature neonate. *The American Journal of Perinatology*. 2002;19(8):435-37.
- [5] Mockel A, Nibler K, Wilhelm T, Handrick W. Neonatal suppurative parotitis. *Klinische Padiatrie*. 2005; 217(2):86-88.
- [6] Mac Dorman MF, Minino AM, Strobino DM, Guyer B. Annual summary of vital statistics 2001. *Pediatrics*. 2002;110:1037-52.
- [7] Ismail EA, Seoudi TM, Al Amir M. Neonatal suppurative parotitis over the last 4 decades: Report of three new cases and review.

Pediatr Int. 2013;55(1):60-64.

- [8] Disouza JN, Geary C, Mukerji S. Neonatal parotid gland enlargement: Is it suppurative parotitis? A case report. Am J Case Rep. 2012;13:41-43.

[9] Singh K. Bilateral Abscess in a Neonate. Indian Pediatr. 2006;43(11):1009-10.

- [10] Coban A, Ince Z, Uçsel R, Ozgeneci A, Can G. Neonatal suppurative parotitis: A vanishing disease? Eur J Pediatr. 1993;12:1004-05.

**AUTHOR(S):**

1. Dr. Rahul Mansing Kadam
2. Dr. VSV Prasad
3. Dr. Sudha Boda.

**PARTICULARS OF CONTRIBUTORS:**

1. Consultant Neonatologist, Department of Neonatology, Lotus Hospitals for Women and Children, Hyderabad, Telangana, India.
2. Chief Pediatric and Neonatal Intensivist, Department of Neonatology, Lotus Hospitals for Women and Children, Hyderabad, Telangana, India.

3. Consultant Pediatrician, Department of Neonatology, Lotus Hospitals for Women and Children, Hyderabad, Telangana, India.

**NAME, ADDRESS, E-MAIL ID OF THE CORRESPONDING AUTHOR:**

Dr. Rahul Mansing Kadam,  
Consultant Neonatologist, Lotus Hospitals for  
Women and Children, Hyderabad,  
Telangana-500004, India.  
Email: drrahul19@gmail.com

**FINANCIAL OR OTHER COMPETING INTERESTS:**

None.

Date of Publishing: Jul 20, 2017