

Congenital Lumbar Hernia with VACTERL Anomaly: A Rare Presentation

MOHD. AAMIR, HARISH PUNIA, KAMAL NAYAN RATTAN, ADITI SINGH, POOJA TRIPATHI

ABSTRACT

Congenital lumbar hernia also known as Lumbocostovertebral syndrome comprises various skeletal abnormalities like hemivertebrae, rib defects, abdominal wall anomalies and abdominal muscle hypoplasia. In this case report we describe a rare case of a neonate presenting with an unusually high number of congenital

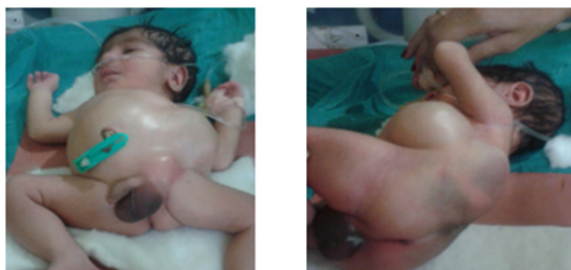anomalies including lumbar hernia, high anorectal malformation, left inguinal hernia, thoracolumbar meningomyelocele, hemivertebrae and right crossed fused ectopic kidney. We intend to describe this rare association and a brief review of literature.

Keywords: Anorectal malformation, Lumbocostovertebral syndrome, Ultrasonography

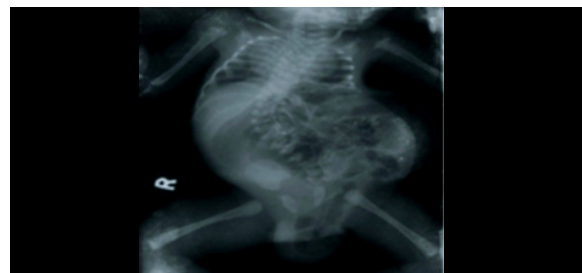CASE REPORT

A full term male neonate was born to a 25 yrs old primi gravida mother by spontaneous normal vaginal delivery. Mother was healthy with no antenatal complications and a supervised antenatal period. Baby weighed 3.2Kg, 48 cm in length and had an occipitofrontal circumference of 33.2cm. There was no history of any drug intake or radiation exposure during pregnancy. Prenatal ultrasonography revealed no abnormality. After initial resuscitation, the neonate was shifted to the neonatal surgical intensive care unit for further evaluation and management. On physical examination, vital signs were stable, except for the gross malformations general condition of baby was good and the activity was noted as fair. The abdomen was grossly distended with a lump in the left lumbar region which increases in size on crying as shown in [Table/Fig-1]. An underlying muscular defect of about 2×1.5 cm was appreciated on palpation. Imperforate anus, a cystic swelling in the back and a swelling in the left inguinal region was also noted. Infantogram [Table/Fig-2] showed a mass

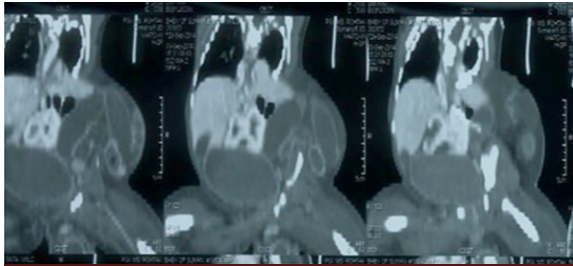
protruding from left lateral lumbar abdominal wall containing bowel loops, hemivertebrae defects of all lumbar vertebrae with a compensated scoliosis that was not apparent on physical examination. Cross-table prone lateral radiographs revealed findings suggestive of a high anorectal malformation. Ultrasonogram (USG) spine showed a cystic swelling of size 5×2cm herniating from lateral element of vertebra in thoracolumbar region suggestive of meningomyelocele. Left kidney was not visualised in left renal fossa however was seen in right side fusing with the right kidney suggestive right crossed fused ectopic kidney. CECT [Table/Fig-3a,b] confirmed all the findings with left lumbar herniation of spleen and bowel loops, right crossed fused ectopia, lumbar hemivertebrae, thoraco lumbar meningomyelocele and left inguinal hernia. DNA microanalysis was not performed, however, chromosomal analysis showed normal male karyotype. In view of multiple anomalies parents refused to give consent for any surgical intervention. Baby expired on day 5 of life due to severe septic shock.



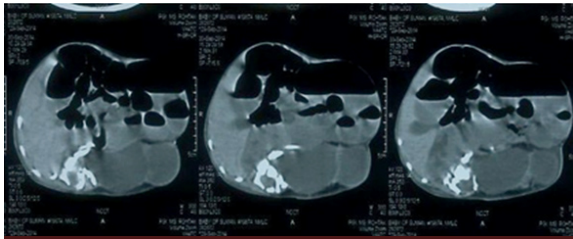
[Table/Fig-1]: shows gross appearance of baby with large lump in the left lumbar region, small swelling in left inguinal region and a cystic swelling over the back



[Table/Fig-2]: Shows the infantogram depicting hemivertebrae of lumbar region with scoliosis and a large abdominal wall defect along with herniation of viscera in the left lumbar region



[Table/Fig-3a]: CECT scan showed crossed fused renal ectopia along with a large lumbar hernia on left side



[Table/Fig-3b]: CECT picture showing large abdominal wall defect on left side

DISCUSSION

The lumbar region is defined anatomically by the erector spinae muscles medially, the external oblique muscle laterally, crest of the iliac bone inferiorly and by the 12th rib superiorly. This space is further divided into superior lumbar triangle of Grynfeltt-Lesshaft and inferior lumbar triangle of Petit [1, 2]. CLH is classified as superior when it occurs through the superior lumbar triangle (Grynfeltt-Lesshaft hernia), inferior when the hernia occurs through the inferior lumbar triangle (Petit hernia), or diffuse when caused by a generalized deficiency of the lumbar muscles. The diffuse type is usually associated with aplasia of the lumbar muscles and is more commonly bilateral [1,2].

About 20 % of Lumbar hernias are congenital and rest are classified as acquired [3]. CLH previously known as Lumbocostovertebral syndrome is a rare syndrome first described by Touloukian in 1972. Etio-pathogenesis of CLH is unclear and it is proposed that a single somatic Mutation in early embryogenesis possibly due to transient anoxia causes derangement of lumbar muscles and aponeuroses resulting in herniation [4].

VACTERL association is a non random occurrence and it includes Vertebral anomalies, Anal atresia, Cardiac anomalies, Tracheoesophageal fistula, Renal abnormalities and Limb defects. It was first described by Quan and Smith in 1973 as VATER association. Most infants with this association syndrome have two or more of the defects listed above. The most common findings include anal atresia, vertebral anomalies, and tracheoesophageal fistula, with occurrences in at least 70% of patients. Renal anomalies occur in approximately 50% of cases [5]. Our case presented with anal atresia, hemivertebrae and right crossed fused ectopic kidney.

Less than 50 cases of congenital lumbar hernia associated with other congenital anomalies have been reported. A case of congenital lumbar hernia associated with VACTERL anomaly is a very rare occurrence with only 3 cases reported in literature [3,6,7]. All these three case reports noted the presence of anorectal malformations with CLH. Our case was most similar to the one reported by Lyngdoh et al., [7]. Harris et al., reported absent ribs in their case but we could not find any obvious rib anomaly in our case [6]. In about 2/3rd of patients with CLH other congenital anomalies like caudal regression syndrome, diaphragmatic hernia, ureteropelvic junction obstruction, cloacal exstrophy, focal nodular hyperplasia of the liver, hydrocephalus, renal agenesis, meningomyelocele, hydrometrocolpos, anorectal malformation, and undescended testis are noted [1]. Renal anomalies reported with CLH include hydronephrosis secondary to ureteropelvic obstruction, crossed-fused renal ectopia and renal agenesis [6]. Hancock et al., reported crossed fused renal ectopia along with CLH a finding similar to our case [8]. Our case is probably the first case reporting congenital lumbar hernia in association with thoracolumbar meningomyelocele and inguinal hernia; we were unable to find a similar case report in literature.

Possible complication of CLH may include incarceration but it is unusual because the neck of sac is generally broad. Early elective surgical intervention to close the defect along with repair using local tissues is the modality of choice [1, 3]. Best time for surgical repair is before first year of life because the hernia defect may enlarge with growth, making primary closure with surrounding tissue difficult. Prosthetic material may be needed if the size of the defect is large or if there is extensive muscular hypoplasia [3, 9].

CONCLUSION

Congenital lumbar hernia with VACTERL anomaly is very rare occurrence very few cases have been reported in literature. Diagnosis of congenital hernia should alert the surgeon, prompting further investigations for various other congenital orthopedic, neurological, and urological anomalies. Open prosthetic repair continues to be the procedure of choice for treating such hernias.

REFERENCES

- [1] Stamatou D, Skandalakis JE, Skandalakis LJ, Mirilas P. Lumbar hernia: surgical anatomy, embryology, and technique of repair. *American Surgeon*. 2009; 75(3): 202-07.
- [2] Lima M, Grandi M, Ruggeri G, Dòmini M, Bianchini MA, Ceccarelli PL, et al. Lumbar hernia as congenital aplasia of lumbo-dorso muscle. *J Pediatr Surg*. 1994;4(2):110-12.
- [3] Wakhlu A, Wakhlu AK. Congenital lumbar hernia. *Pediatric Surgery International*. 2000; 16(1-2):146-48.
- [4] Touloukian RJ. The lumbocostovertebral syndrome: a single somatic defect. *Surgery*. 1972; 71(2):174-81.
- [5] Rittler M, Paz J, Castilla E. VACTERL Association, epidemiologic definition and delineation. *Amer J of Med*

- Genetics*. 1996; 63(4): 529-36.
- [6] Harris K, Dorn C, Bloom B. Lumbocostovertebral syndrome with associated VACTERL anomalad: a neonatal case report. *Journal of Perinatology*. 2009; 29(12): 826-27.
- [7] Lyngdoh TS, Mahalik S, Naredi B, Samujh R Khanna S. Lumbocostovertebral syndrome with associated VACTERL anomaly. *Journal of Pediatric Surgery*. 2010; 45(9): e15-17.
- [8] Hancock B, Wiseman NE. Incarcerated congenital lumbar hernia associated with the lumbocostovertebral syndrome. *J Pediatr Surg* . 1988; 23(8): 782-83.
- [9] Akcora B, Temiz A, Babayigit C. A different type of congenital lumbar hernia associated with lumbocostovertebral syndrome. *J Peadiatr surg* .2008;43(1):e21-23.

AUTHOR(S):

1. Dr. Mohd. Aamir
2. Dr. Harish Punia
3. Dr. Kamal Nayan Rattan
4. Dr. Aditi Singh
5. Dr. Pooja Tripathi

PARTICULARS OF CONTRIBUTORS:

1. Fellow (Neonatology), Division of Neonatal Services, Department of pediatrics, PGIMS, Rohtak, Haryana, India.
2. Junior Resident, Department of Pediatrics, PGIMS, Rohtak, Haryana, India.
3. Head and Senior Professor, Department of Pediatric Surgery, PGIMS, Rohtak, Haryana, India.

4. Junior Resident, Department of Pediatrics, PGIMS, Rohtak, Haryana, India.
5. Junior Resident, Department of Pediatrics, PGIMS, Rohtak, Haryana, India.

NAME, ADDRESS, E-MAIL ID OF THE CORRESPONDING AUTHOR:

Dr. Mohd. Aamir,
Fellow (Neonatology), Division of Neonatal Services,
Department of Pediatrics, PGIMS, Rohtak, Haryana,
India.
Email: aamir_klove@yahoo.com

FINANCIAL OR OTHER COMPETING INTERESTS:

None.

Date of Publishing: Jul 01, 2015